



## Identification of Prostate Tissue Structures and Lesions by Vibro-acoustography: An In-vitro Study

PACS: 43.25.Qp

A. Alizad, F. G. Mitri, B. J. Davis, J. F. Greenleaf, and M. Fatemi  
Mayo Clinic College of Medicine  
Rochester, MN USA, [aza@mayo.edu](mailto:aza@mayo.edu)

### ABSTRACT

Vibro-acoustography (VA) is an imaging modality that uses the radiation force of ultrasound to vibrate the tissue at a low frequency and records the resulting acoustic field to produce an image that is related to the stiffness of the tissue. This method provides additional information not available from B-mode ultrasound. VA is sensitive to object properties at ultrasound frequencies, as well as audio (low) frequencies. The purpose of this study is to explore the potential of VA in prostate imaging. Tissue stiffness is an important marker of malignancy in prostate and is often used in digital rectal examination to identify prostate cancer. However, deep or small lesions are not accessible to the examining finger. The ultrasound beam of VA can penetrate deep into prostate. In addition, spatial resolution of VA is much better than a palpating finger. In this study, VA imaging and radiography were performed on 12 prostatectomy specimens fixed in formaldehyde. VA images at different depths show normal prostate tissue structure and borders, urethra, calcification, and lesions. In addition, VA images of the prostates exhibit significant contrast between the central and peripheral zones of the prostate. The results indicate that, with further development, VA may become a new class of imaging tool for prostate imaging.

### Introduction

Prostate cancer is the second common cause of cancer related death. Because of tremendous increase of prostate carcinoma in industrial countries need to imaging technology is constantly increasing. Technological advances of different imaging modalities seem to reassess the role of imaging in prostate cancer [1]. National Institute of Clinical Excellence in its guidelines recommended that magnetic resonance imaging (MRI) is the imaging method of choice for staging prostate cancer [2]. MRI is preferred imaging modality over other methods like ultrasound and CT scan in identifying zonal anatomy of the prostate gland [3, 4 5]. MRI is also the most accurate method of staging prostate cancer [6]. However, various newer studies have reported that MRI is not the perfect imaging modality; microscopic and early macroscopic invasion cannot be reliably shown using current technology [7]. CT scan is largely used to detect nodal enlargement in the pelvis and metastatic disease elsewhere [8,9]. Prostatic ultrasound imaging was only achieved after the practical use of transrectal sonography in 1967. At present, Ultrasound is an indispensable tool for diagnosis in any organ in the field of nephrourology. Because of its non-invasive nature, transrectal ultrasound is the best method for the purpose of identifying the prostate lesion, lesion biopsy and prostate cancer staging [10,11].

The role of imaging in prostate cancer is continuing to evolve. This paper presents a new imaging modality called vibro-acoustography (VA) that we have used to image prostate tissues.

### METHODS AND RESULTS

**Principles of vibro-acoustography (VA):** VA is based on the “*radiation force*” of ultrasound. The radiation force is a nonlinear phenomenon in wave propagation. [12,13]. The general principle of vibro-acoustography is illustrated in Figure 1.

A vibro-acoustography image depicts two types of information about the object: 1) Ultrasonic properties such as the scattering and power absorption characteristics, those are also present in conventional ultrasonography. 2) The dynamic characteristics of the object at frequency  $\Delta f$ , which describe how the object responds to a vibrating force which are related to object stiffness and damping [14]. A number of experiments have been conducted to evaluate its utility in various applications. Vibro-acoustography has been used for imaging in several *in vitro* experiments heart valves [15], vessels [16], breast tissues [17,18,19 ] liver tissues [20]. Recently, VA is being used for imaging human breast lesions in female volunteers [21, 22].

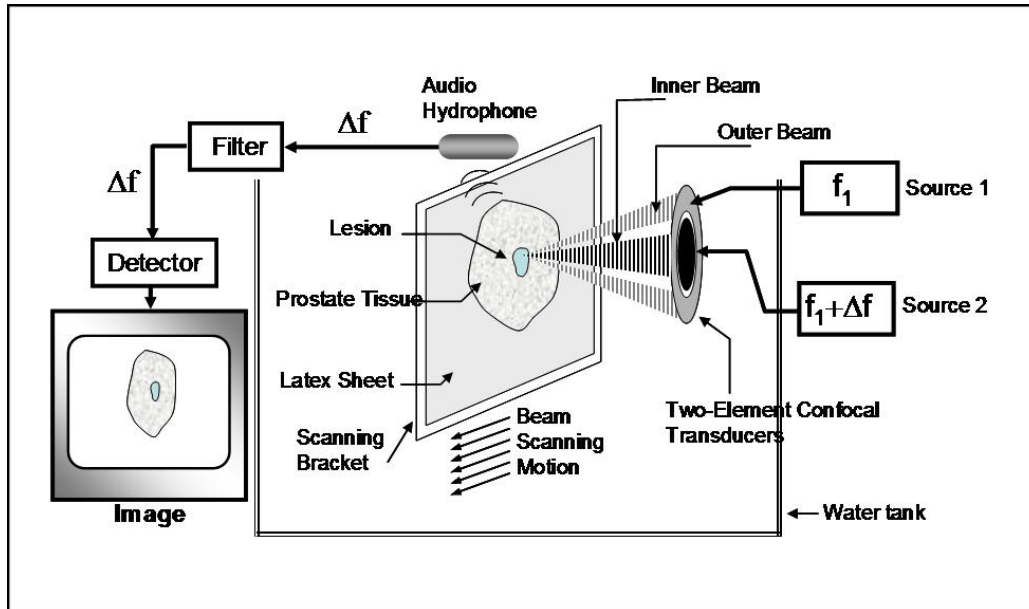


Figure 1.- Experimental VA system diagram. The prostate sample is placed on a bracket inside a water tank and is scanned by the ultrasound from the confocal transducer focused at a desired depth inside the sample. The two ultrasound beams differ in frequency by  $\Delta f$ . The hydrophone receives the acoustic emission at  $\Delta f$  from the sample. This signal is processed and mapped into an image. [Modified with permission from [19]]

### Imaging prostate

In this study, 12 excised human whole prostates were used. The samples were fixed in formaldehyde and then embedded in gel to simulate the *in vivo* condition. The blocks of gel including the prostates were scanned by VA. A confocal transducer at 3 MHz with a difference frequency of  $\Delta f = 50$  kHz was used. The focal length and aperture size of the confocal transducer were 7 cm and 4.5 cm, respectively. The scan covered an image area of 5x5 cm with pixel size of 0.2x0.2mm. The samples were also imaged by high-resolution x-ray. Position of prostate tissue in VA system is shown in Figure1.

### Results

A total of 12 prostates have been scanned by vibro-acoustography. VA images were compared to prostate tissue x-ray and ultrasound. We were able to see the anatomical details as well as microcalcification and lesions in prostate tissues. We categorize anatomical details to three groups: prostate margin, periprostatic fat and urethra. Prostate margin was seen in all VA images of the prostates. Urethra was identified in 11 out of 12 VA images of the prostate. In eight out of 12 VA images of the prostates, the periprostatic fat could be clearly identified. In seven of 12 VA images of prostates some calcifications were identified, which were later verified by x-ray. Lesions were identified in the VA images of three samples and were verified by x-ray.

Figure 2 shows a prostate tissue sample. This figure demonstrates that in VA we are able to see all the anatomical details of prostate.

Figure 3 and 4 demonstrate that x-ray-proven calcifications are identifiable by VA images in two different prostate tissues.

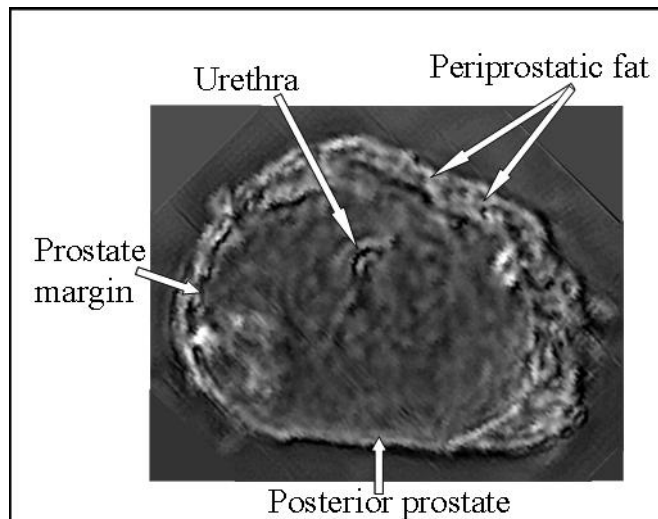


Figure 2- VA image of an excised prostate showing an axial section. This image with  $\Delta f = 6$  kHz shows clear anatomy of the prostate as compared to visible inspection of the section. Noted are periprostatic fat, urethra, posterior prostate and the prostate margin. Unlike ultrasound imaging, VA images have no speckle. (Reproduced with permission from [23]).

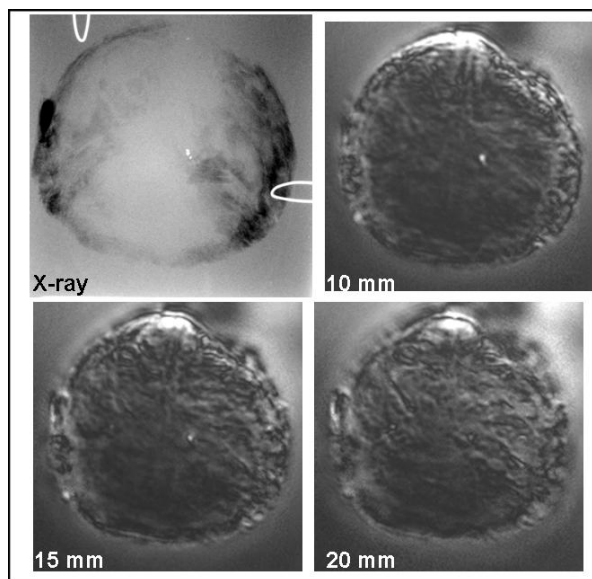


Figure 3. X-ray and VA images of a prostate at different depths are shown. Calcification is noted in all images.

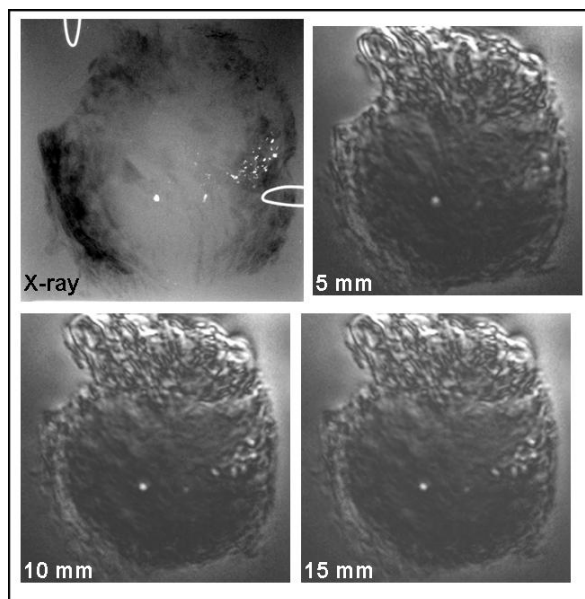


Figure 4. X-ray and VA images acquired at different depths are shown. Calcifications are clearly seen at all depths in VA, especially at 10 and 15 mm, as confirmed by X-ray.

## CONCLUSIONS

In this paper, we presented a non-invasive imaging method for prostate tissue. The experiments on prostate tissues demonstrated the capability of vibro-acoustography in identifying prostate tissue structures, calcification, and lesions. The results indicate that with further development, VA may become a new class of imaging tool for prostate imaging. The future goal of this research is to develop a clinical vibro-acoustography system for in vivo prostate imaging.

## Acknowledgements

Authors are grateful to Randal R. Kinnick for laboratory support. Work supported by NIH Grants EB00535 and CA 91956.

**Disclosure:** Parts of the techniques presented here are patented by MF and JFG.

## References:

- [1] B. N. Bloch, T. Helbich, G. Heinz-Peer: Prostatic carcinoma: current status of diagnostic imaging. *Wien Med Wochenschr Suppl.* **113** (2002) 89-91.
- [2] S. D. Heenan: Magnetic resonance imaging in prostate cancer. *Prostate Cancer & Prostatic Diseases* **7 no.4** (2004) 282-8.
- [3] Y. Nasu, T. Murakami: Clinical role of magnetic resonance imaging (MRI) of prostatic cancer. *Nippon Rinsho.*; **56 no. 8** (1998) 2042-5.
- [4] A. Rajesh, F. V. Coakley: MR imaging and MR spectroscopic imaging of prostate cancer. *Magnetic Resonance Imaging Clinics of North America* **12 no. 3** (2004) 557-79.
- [5] S. Adusumilli, E. S. Pretorius: Magnetic resonance imaging of prostate cancer. *Seminars in Urologic Oncology* **20 no.3** (2002) 192-210.
- [6] H. M. Pollack: Imaging of the prostate gland. *European Urology.* **20 Suppl 1** (1991) 50-8 1.
- [7] S. D. Heenan: Magnetic resonance imaging in prostate cancer. *Prostate Cancer & Prostatic Diseases.* **7no.4** (2004) 282-8.
- [8] R. J. Burcombe, P. J. Ostler, A. W. Ayoub, P. J. Hoskin: The role of staging CT scans in the treatment of prostate cancer: a retrospective audit. *Clin Oncol (R Coll Radiol).* **12 no. 1** (2000) 32-5.
- [9] A. Zissimopoulos, A. Zanglis, D. Andreopoulos, N. Baziotis: The role of <sup>99m</sup>Tc(V)-DMSA scan as compared to <sup>99m</sup>Tc-MDP and CT scans in imaging the primary tumor and metastases of osteosarcoma., *Hell J Nucl Med* **8 no. 3** (2005) 162-4.
- [10] H. Watanabe: History of ultrasound in nephrourology. *Ultrasound Med Biol.* **27 no. 4** (2001) 447-53.

- [11] H. Watanabe: Diagnostic imaging of the prostate Nippon Hinyokika. Gakkai Zasshi - Japanese Journal of Urology **82 no. 1** (1991) 1-15.
- [12] M. Fatemi, J. F. Greenleaf: Ultrasound stimulated vibro-acoustic spectroscopy. Science **280** (1998) 82-85.
- [13] M. Fatemi, J. F. Greenleaf: Vibro-acoustography. An imaging modality based on ultrasound stimulated acoustic emission. Proc. Nat. Acad. Sci. USA **96** (1999) 6603-6608.
- [14] A. Alizad, M. Fatemi: Breast Vibro-acoustography. In: Suri, J. S., Rangayyan, R. M., Laxminarayan, S. Eds.: *Emerging Technologies in Breast Imaging and its Applications*. American Scientific Publishers (ASP), Valencia, USA, **Chapter 11** (2007)
- [15] A. Alizad, M. Fatemi, R. A. Nishimura, R. R. Kinnick, E. Rambod, J. F. Greenleaf: Detection of calcium deposits on heart valve leaflets by vibro-acoustography: an in vitro study. Journal of the American Society of Echocardiography **15 no. 11** (2002) 1391-1395.
- [16] M. Fatemi, J. F. Greenleaf: Probing the dynamics of tissue at low frequencies with the radiation force of ultrasound. Phys. Med. Biol. **45** (2000)1449-1464.
- [17] M. Fatemi, , L. E. Wold, A. Alizad, and J. F. Greenleaf: Vibro-acoustic tissue mammography. IEEE Transactions on Medical Imaging **21 no. 1** (2002) 1-8.
- [18] Alizad, A., M. Fatemi, L. E. Wold, and J. F. Greenleaf: Performance of vibro-acoustography in detecting of microcalcifications in excised human breast tissue: a study on 74 breast tissue samples. IEEE Transactions on Medical Imaging **23 no. 3** (2004) 307-312.
- [19] A. Alizad, M. Fatemi, D. H. Whaley, and J. F Greenleaf: Application of vibro-acoustography for detection of calcified arteries in breast tissues. Journal of Ultrasound in Medicine **23** (2004) 267-273,
- [20] A. Alizad, L. E. Wold, and J. F. Greenleaf, M Fatemi: Imaging mass lesions by vibro-acoustography: Modeling and experiment. IEEE Transactions on Medical Imaging **23 no. 9** (2004)1087-93.
- [21] A. Alizad, J. F Greenleaf, M. Fatemi: Potential Applications of Vibro-acoustography in Breast Imaging. Technol Cancer Res Treat **4 no. 2** (2005) 151-8.
- [22] A. Alizad, D.H. Whaley, J. F. Greenleaf, M. Fatemi: Critical Issues in Breast Imaging by Vibro-acoustography. Ultrasonics (2006) e217-220.
- [23] J. F. Greenleaf, R. R. Kinnick, M. Fatemi, B. J. Davis: Imaging prostate brachytherapy seeds with pulse-echo ultrasound and vibro-acoustography. In: Arnold W , Hirsekorn S: *Acoustical Imaging*. 2004 Kluwer Heidelberg Publishers, Netherlands, **2** (2004) 555-561,.